



# IJEAST

INTERNATIONAL JOURNAL  
OF ENGINEERING APPLIED SCIENCE  
AND TECHNOLOGY



**VOLUME :**

**Special Issue**

**Print / Issue Publication Date: 15-Sep-2020**



**ISSN : 2455-2143**



Indexed In



[WWW.IJEAST.COM](http://WWW.IJEAST.COM)

[editor@ijeast.com](mailto:editor@ijeast.com)

# EFFECTIVENESS OF X-RAY AND FUNCTIONAL DIAGNOSTIC METHODS FOR STOOL INCONTINENCE IN CHILDREN

Shamsiev A.M.  
Samarkand State Medical  
Institute, Republic of  
Uzbekistan

Shamsiev J.A.  
Samarkand State Medical Institute,  
Republic of Uzbekistan

Saidov M.S.  
Samarkand State Medical Institute,  
Republic of Uzbekistan

**Abstract:** In this research, we studied the various causes of stool incontinence in 102 children after performed primary anorectal surgery. And also for the choice of treatment tactics, complex X-ray-functional studies were carried out, which allow to assess the degree of disorders of the sphincter apparatus of the rectum.

Incontinence of stool in children is one of socially significant problems leading to a significant worsening in the quality of life of the child [1, 2]. Causal factors can be divided into 2 groups. The first – associated with damage to the sphincter apparatus of the rectum. In this case, the reason, most often, is the inadequate surgical correction of the pathology of the anorectal region, the percentage of unsatisfactory results at which it reaches 60% [3, 4, 5]. The second group is disorders of the neuromuscular apparatus of the rectum without damaging the anatomical structures [2, 6, 7]. Most often these conditions are caused by a chronic stasis of big intestine. According to some data [7], in 3% of patients with chronic constipation, there is a presence of stool smearing of varying severity.

Diagnosis and surgical correction of these disorders requires a comprehensive application of labor-intensive, high-tech research methods. In this case, great importance is attached to radiographic and functional methods, but their role in the selection of therapeutic tactics is not fully understood [2, 5]. Despite a large number of studies, this direction in pediatric coloproctology remains not fully developed.

**The purpose of our investigation** was to study the effectiveness of X-ray and functional diagnostic methods in the selection of therapeutic tactics for stool incontinence in children.

**Material and methods of investigation.** From 2000 to 2015, under our observation, there were 102 children with stool incontinence. Depending on the etiologic factor, all children were divided into 3 groups:

The first group consisted of 74 children operated on for stool incontinence of various degrees, associated with damage to the sphincter apparatus of the rectum with correction of anorectal defect or rectal injury.

The second group consisted of 28 girls with stool incontinence caused by the presence of fistula from the rectum in the reproductive system (H-fistulae), all children of this group were surgically operated.

The control group consisted of 10 children without pathology of the anorectal zone. The age of the investigated patients varied from 3 to 15 years old.

All children were performed the complex examination: collection of case history, examination of the anorectal zone with digital rectal examination, ultrasound investigation (USI) of the organs of the abdominal cavity and retroperitoneal space, X-ray methods with contrasting of the big intestine and rectum, endoscopy, neurohistochemical methods of rectal examination.

To exclude agangliosis or stenosis of the big intestine, transanal contrast irrigography was performed for all children of the first and second groups.

For objective study of functional disorders of the sphincter apparatus of the rectum, 45 children were carried out cinema-defecography and 38 children were carried out anal manometry. Cinema-defecography was performed on the Phillips apparatus (Holland) without any preliminary preparation. The technique of defecography was presented by Mahieu et al. [8]. In the position of the child on the left side, a moderately dense consistency of barium is rectally administered until the urge to defecate. We note at once that in children who underwent abdominal-perineal proctoplasty by the Rebein type, the formation of the required volume was represented by technical difficulties, which was resolved by groups of the density of the barium administered. The anus is marked with barium porridge. After that, the child is emptied on a special bedpan, allowing X-rays to pass through. At the same time, the amount of barium administered before the first urge is estimated, the ability to keep the enema from the place where contrast is introduced to the plastic ship.

At the doctor's signal, an act of defecation is performed under visual control during defecoscopy. At the same time, digital recording is made (in our case, the Panasonic GS300 digital video camera – Japan) with the possibility of subsequent viewing on a personal computer.

The magnitude of the anorectal angle was measured during rest, bowel movements and after emptying the rectum, rectal size, ratio of the rectum to the sacrum also were measured.

Besides the measurement of the posterior and middle anorectal angle, the length of the anal canal was made; great attention was paid to the gradient of the anorectal angle, which was determined by the difference in the posterior anorectal angle during defecation and rest (Figure 1).

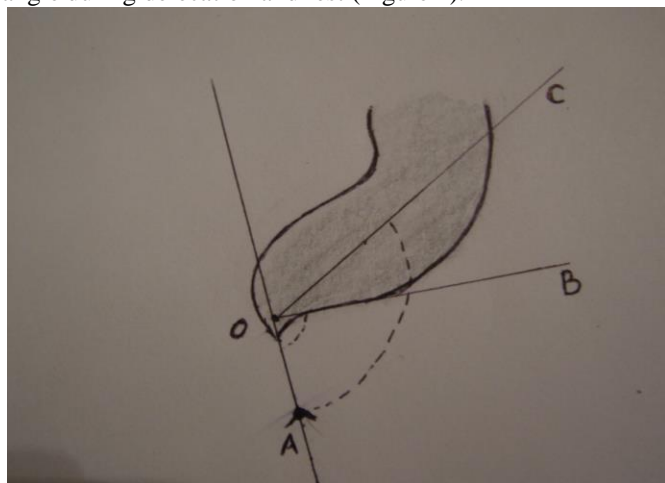


Figure 1. The measurement scheme of anorectal angle and anal canal. AOB – posterior anorectal angle; AOC – the middle anorectal angle

**Table 1. The degree of change in the posterior anorectal angle of children with incontinence after staging of anorectal malformations**

Investigated groups	Amount of children	Amount of investigations	Posterior anorectal angle (in degrees)		
			At rest	During defecation	Gradient
Posterior-sagittal reanorectoplasty	30	19	93±1,3	119±0,3	26±0,8
Abdominal-perineal reprotoptasty	21	11	110±1,3	117±2,1	7±1,7
Perineal reprotoptasty	23	8	100±0,7	120±0,4	20±0,55

Just like in the children of the first group, the worst result was noted in children who underwent abdominal-perineal reprotoptasty with endorectal demucosation of the rectum. It should be noted that the stool incontinence was in 100% of children who underwent this plastic. The smooth-muscle leiomyoplasty in our modification (author's certificate RK No. 14258) gives only a temporary positive effect for 18-24 months, but at the same time improves the degree of anal incontinence from the third to the second. Defecography with measurement of the posterior anorectal angle was at a gradient level of 7 degrees. And the back anorectal angle was within 110-120 degrees.

In children who underwent perineal reprotoptasty (sphincterelovatoroplasty, levatoroplasty, anterior sagittal reanorectoplasty), the results were better however, and here the degree of anal incontinence remained at 65-70% after repeated operation. It should be noted that this subgroup was

The next investigated parameter was the determination of the degree of compression of the anal canal, which we determined by the method proposed by P.J. Shorvon et al. [9]. During defecographies, the degree of compression of the anal canal and the extent of the cone-shaped rectoanal segment were determined. There are 5 degrees of compression: 1<sup>st</sup> degree – the cone of the rectoanal segment does not enter the anal canal; 2<sup>nd</sup> degree – the cone less than 50% of the anal canal; 3<sup>rd</sup> – the cone more than 50% of the anal canal; 4<sup>th</sup> unexplained gaping of the anal canal with a short distal sphincter zone; 5<sup>th</sup> degree – significant gaping of the anal canal.

Anal manometry was made to 38 children on the "Solar MMS" apparatus (Netherlands). The pressure of the anal canal and rectum at rest and tension, as well as the length of the anal canal were assessed. Particular attention was paid to the presence of rectoanal inhibitory reflex (RAIR).

The degree of stool incontinence was determined according to the international Krikenbek classification [11].

The results of the study were statistically processed with using the Student's criterion.

**Results and discussion.** In the first group of children with stool incontinence, which develops after surgical interventions and correction of anorectal malformations, the degree of stool incontinence was heavier (2-3 degrees). The size of the posterior anorectal angle in children of this group was large, the gradient was smaller (Table 1).

composed of children undergoing surgery for low anorectal malformations, with adequate primary correction of which the stool incontinence rate should be low (10-14%).

The second subgroup consists of 30 children with stool incontinence after correction of anorectal malformations underwent to posterior-sagittal reanorectoplasty. Most of them were children after correction of high developmental malformations and with rough cicatricial changes after correction of low forms of anorectal malformations. The gradient of the posterior anorectal angle in these patients varied at a level of 25 degrees, and the back anorectal angle itself was within 95-100 degrees.

Functional examinations have shown a decrease in the pressure of rest and compression. At the same time, after perineal proctoplasty and posterior sagittal reanorectoplasty, RAIR was noted with a result of 90-100%, after the abdominal perineal proctoplasty the RAIR was not possible to identify in

either case. All children underwent courses of rehabilitation therapy for 36-42 months after the operation.

In 28 girls of the second group, stool incontinence was due to the presence of a fistula in the reproductive system. Rectovaginal fistula was diagnosed in 3 (10,7%), rectovestibular fistula in 25 (89,3%) patients. X-ray examination was applied to 9 children with rectovestibular fistula by contrasting the distal rectum with balloon technique [10]. This examination allows us to determine the length and height of the fistula localization, although all recto-vestibular fistulas were located low.

Invagination extirpation of the fistula was performed in 8 (28,6%) children; from them: 1 child – with rectovaginal and 7 – with rectovestibular fistula, 2 (7,1%) of children were operated by transperineal access, both patients had rectovaginal fistula.

18 (64.3%) children with rectovestibular fistula, anterior anorectoplasty of the canal with extirpation of the fistula and anterior wall of the rectum lowering beyond the anal canal in our modification (positive decision No. 2007/0642.1) were performed.

In 8 children who underwent invagination extirpation of the fistula, recurrence fistula was noted in 6, in one patient the fistula was closed by secondary healing of the wound with the development of rough scars on the eve of the vagina and diverticulum of the rectum. 5 children with recurrences were repeatedly operated (anterior reanorectoplasty with extirpation of the fistula and bringing down of the anterior wall of rectum was performed).

From the 2 girls who underwent transperineal access, the recurrence of fistula was noted in both patients who had been repeatedly operated (anterior reanorectoplasty with extirpation of the fistula and bringing down of the anterior wall of rectum was performed) with a satisfactory result. At the same time, one child with recurrence of a wide rectovaginal fistula was prevented with colostomy, which was closed in 1 month after the fistula was eliminated.

18 girls with recto-vestibular fistulas immediately underwent anterior reanorectoplasty with fistula extirpation and bringing down of the anterior wall of rectum by the method which described above. There was no recurrence of the fistula, but one patient on the 7th day had a complication of bleeding from the operating wound. He was repeatedly operated to eliminate bleeding with a satisfactory result.

Long-term results were studied in 24 patients from 6 months to 6 years after the operation. Stool smearing of the 1 degree (rare) was noted in 5 children, 3 children suffered constipation, which is regulated by laxatives. Stool smearing was noted in children who underwent repeated surgery due to the recurrence of the fistula.

Defecography performed by 7 children of this group did not show any significant changes in the posterior anorectal angle, however, in children who underwent invagination extirpation of the fistula, there is a certain displacement of the anterior wall of the rectum anteriorly, probably due to a scar

process involving the anterior wall of the rectum and posterior wall of the vagina. In functional examinations, RAIR was noted with an index of 100%, however, after the invagination extirpation of the fistula, a decrease in the resting and compressive pressure along the front surface is noted.

Thus, stool incontinence as a syndrome can have various causative factors, and the stool incontinence itself greatly reduces the quality of life, isolating the child from a full-fledged social life. To select the most rational tactics, a complex of roentgen-functional examinations is needed to assess the extent of disorders of the sphincter apparatus of the rectum. The carried out analysis of the methods of surgical correction allows us to make the following conclusions:

1. The method of the choice of repeated plastic after correction of anorectal malformations is posteriorsagittal reanorectoplasty, which allows to optimally restoring the disordered anatomy of the anorectal zone.
2. In case of stool incontinence, due to the presence of a fistula from the rectum in the reproductive system of girls, the method of choice is to bringing down the anterior wall of the rectum with the fistula beyond the anal canal in our modification, to avoid recurrences and damage to the sphincter apparatus of the rectum.

#### References

1. Pena A., Vries P.A. Posterior sagittal anorectoplasty. Important technical considerations and new applications. //J. Pediatr. Surg. – 1982. – № 17. – P. 796-811.
2. Lenushkin A.I. Surgical coloproctology of the children age. M.: Medicine. – 1999. – 365 pages.
3. Smirnov A.N., Stepanov Э.А., Poddubniy I.V. Sacral proctoplasty in the treatment of anorectal malformations in children. //Bulletin of Russia. – 1994. – № 3. – P. 53-56.
4. Mazur V.G., Komissarov I.A., Yalfimov A.N. Complex radial examination in the defecation disorders in children. //Bulletin of Surgery. – 2001. – № 6. – P. 54-58
5. Pena A., Grasshoff S., Levitt M. //J.Pediatr. Surg. – 2007. – Vol. 42. – P. 318-325.
6. Alieva E.A. Stool incontinence in children. //Pediatric. – 2003. – № 5. – P. 82-85
7. Rasquin-Weber A., Hyman P., Cucchiara S. et al: Childhood functional gastrointestinal disorders. //Gut. – 1999. – Vol. 45. – P. 1160-1168.
8. Mahieu P., Pringot J., Bodart P. Defecography: I. Description of a new procedure and results in normal patients. //Gastrointest Radiol. – 1984. – Vol. 9. – P. 247-51.
9. Shorvon P., McHugh S., Diamant N. et al: Defecography in normal volunteers: results and implications. //Gut. – 1989. – Vol. 30. – P. 1737-1749.
10. Tsushida Y., Saito S., Honna T et al: Double termination of the alimentary tract in females: A report of 12 cases

and literature review. //J. Pediatr Surg. – 1984. – Vol. 19.  
– P. 292-296.  
11. Holdschneider A., Hutson J., Pena A. et al. Preliminary  
report on the International Conference for the

Development of Standards for the Treatment of Anorectal  
Malformations. //J. Pediatr.Surg. – 2005. – Vol. 40. – P.  
1521-1526.

# IJEAST

INTERNATIONAL JOURNAL  
OF ENGINEERING APPLIED SCIENCE  
AND TECHNOLOGY

## ABOUT IJEAST

International Journal of Engineering Applied Science and Technology (IJEAST) is a peer-reviewed, open access journal that publishes high-quality research papers in the field of Engineering, Applied Science and Technology.

IJEAST aims to provide a platform for researchers, academicians, and professionals to share their innovative ideas, research findings, and practical experiences with the global scientific community.

## FOCUS AREAS

- Engineering
- Applied Science
- Technology
- Innovation & Development
- Interdisciplinary Studies



### PEER REVIEWED

All submissions are rigorously peer reviewed to ensure quality.



### OPEN ACCESS

Free and unrestricted access to research for all.



### GLOBAL REACH

Connecting researchers and professionals worldwide.



### TIMELY PUBLICATION

We ensure a swift and efficient publication process.



For more information, visit our website  
[www.ijeast.com](http://www.ijeast.com)



INTERNATIONAL JOURNAL  
OF ENGINEERING APPLIED SCIENCE  
AND TECHNOLOGY

✉ [editor@ijeast.com](mailto:editor@ijeast.com)

🌐 [www.ijeast.com](http://www.ijeast.com)

📍 India



2455-2143